

CASE REPORT

1. Doctor in Clinical Medicine, Specialist in Obstetrics and Gynecology, Obstetrics and Gynecology Service, Hospital Central "Dr. Urquinaona", Maracaibo, Zulia State, Venezuela. ORCID 0000-0002-5433-7149

Ethical statement

Acknowledgement of authorship: All authors declare that we have contributed to the idea, study design, data collection, data analysis and interpretation, critical review of the intellectual content, and final approval of the manuscript we are submitting.

Ethical responsibilities: Protection of persons. We the authors declare that the procedures followed conformed to the ethical standards of the responsible human experimentation committee and in accordance with the World Medical Association and the Declaration of Helsinki.

Confidentiality of data: The authors declare that we have followed the protocols of the Ecuadorian Institute of Social Security on the publication of patient data.

Right to privacy and informed consent: The authors have obtained the informed consent of the patients and/or subjects referred to in the article. This document is in the possession of the corresponding author.

Funding: The authors certify that we have not received financial support, equipment, personnel, or in-kind support from individuals, public and/or private institutions for the study.

Received: 7 December 2021

Accepted: 2 March 2022

Online publication: 24 June 2022

Corresponding author:

Dr. Eduardo Reyna-Villasmil

📍 Central Hospital "Dr. Urquinaona" Final
Av. El Milagro, Maracaibo, Estado Zulia,
Venezuela

☎ 584162605233

✉ sippenbauch@gmail.com.

Cite as: Reyna-Villasmil E. Prenatal diagnosis of Delleman-Oorthuys syndrome. *Rev Peru Ginecol Obstet.* 2022;68(2). DOI: <https://doi.org/10.31403/rpgo.v68i2416>

Prenatal diagnosis of Delleman-Oorthuys syndrome

Diagnóstico prenatal de síndrome de Delleman-Oorthuys

Eduardo Reyna-Villasmil¹

DOI: <https://doi.org/10.31403/rpgo.v68i2416>

ABSTRACT

Delleman-Oorthuys syndrome (oculocerebrocutaneous syndrome) is a rare, congenital, sporadic disorder characterized by microphthalmia/anophthalmia with or without orbital cysts, focal skin defects, and intracranial alterations. Due to an asymmetric distribution of the clinico-radiological features, absence of recurrence within the family and its higher frequency in males, the possibility of somatic mosaicism or sporadic mutations in the fifth or sixth week of fetal development has been proposed. Suggested minimal diagnostic criteria include microphthalmia or orbital cysts, central nervous system cysts or hydrocephalus, and focal skin defects. Given the variability of manifestations and overlap with other syndromes, diagnosis can be difficult, but prenatal detection of this rare congenital anomaly with cerebral malformations is crucial in the management of newborns. Imaging studies for evaluation of features are helpful in the identification and differentiation of cases. A case of prenatal diagnosis of Delleman-Oorthuys syndrome is presented.

Key words: Delleman-Oorthuys syndrome, Eye anomalies, Cutaneous anomalies, Cerebrum anomalies, Prenatal diagnosis.

RESUMEN

El síndrome de Delleman-Oorthuys (síndrome oculocerebrocutáneo) es un trastorno esporádico, congénito y poco frecuente caracterizado por microftalmia / anoftalmia con o sin quistes orbitales, defectos cutáneos focales y alteraciones intracraneales. Debido a la distribución asimétrica de las características clínico-radiológicas, ausencia de recurrencia dentro de la familia y su mayor frecuencia en el sexo masculino, se ha propuesto la posibilidad de mosaicismo somático o mutaciones esporádicas en la quinta o sexta semana de desarrollo fetal. Los criterios diagnósticos mínimos sugeridos incluyen microftalmia o quistes orbitales, quistes del sistema nervioso central o hidrocefalia y defectos focales de piel. Dada la variabilidad en las manifestaciones y la superposición con otros síndromes, el diagnóstico puede ser difícil, pero la detección prenatal de esta rara anomalía congénita con malformaciones cerebrales es crucial en el manejo de los recién nacidos. Los estudios por imágenes para la evaluación de las características son útiles en la identificación y diferenciación de los casos. Se presenta un caso de diagnóstico prenatal de síndrome de Delleman-Oorthuys.

Palabras clave. Síndrome de Delleman-Oorthuys, Anomalías del ojo, Anomalías cutáneas, Anomalías cerebrales, Diagnóstico prenatal.

INTRODUCTION

Delleman-Oorthuys syndrome (DOS), or oculocerebrocutaneous syndrome, is a rare, congenital, sporadic oculoneurocutaneous disorder with no known hereditary pattern. It is characterized by periorbital cutaneous appendages, palpebral anomalies, anophthalmia or microphthalmia, orbital cysts, focal alopecia, hypoplastic or aplastic cutis and cerebral alterations such as intracranial cysts and agenesis of the corpus callosum, which is more common in males⁽¹⁾. It was first described in 1981 and since then there are reports of about 50 cases, being those diagnosed prenatally very rare⁽²⁻⁴⁾. A case of prenatal diagnosis of Delleman-Oorthuys syndrome is presented.

CASE REPORT

The patient was 18-year-old, primigravida, who was referred for prenatal high-risk consultation at 26 weeks of gestation due to ultrasound findings of choroid plexus cysts and absence of cerebellar vermis. The patient de-

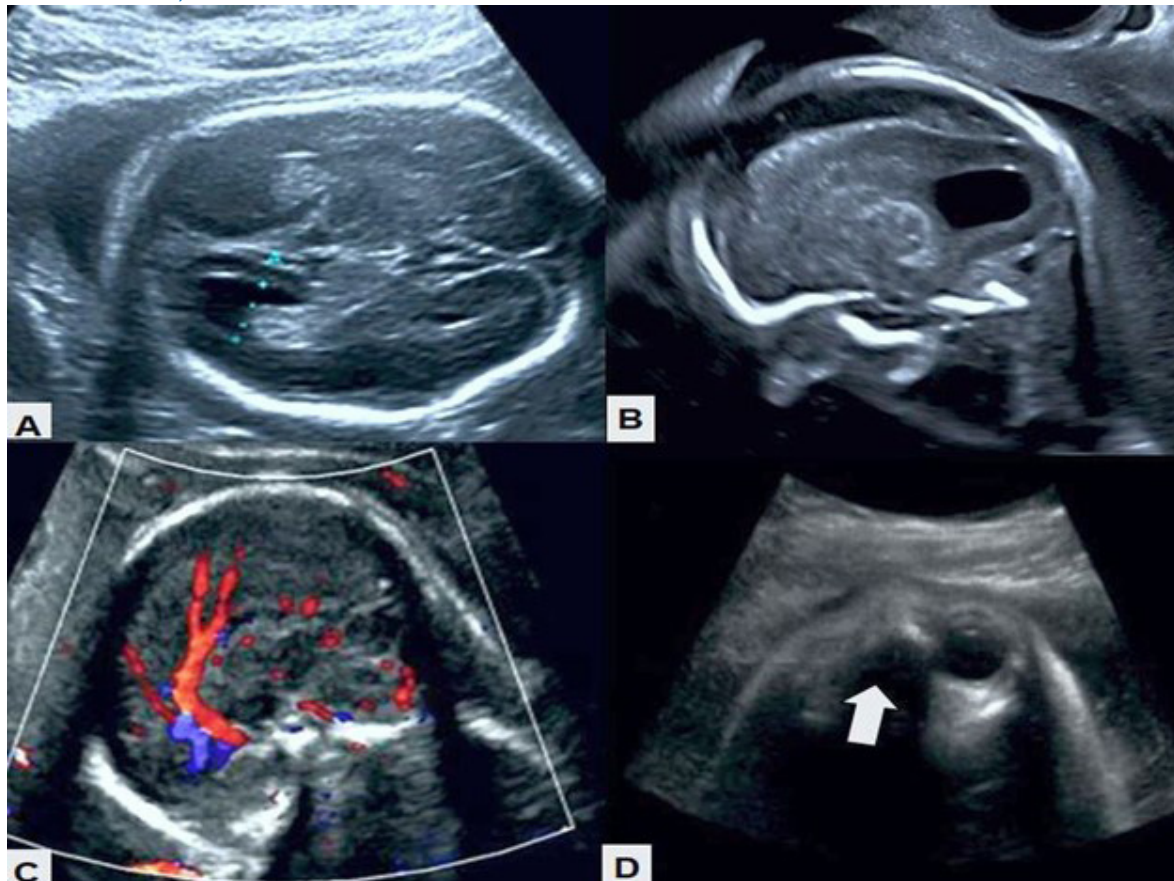
nied a personal history of seizures, exposure to teratogens, consanguineous ties to her partner, and central nervous system disorders in first-degree relatives.

The ultrasound evaluation performed in the department showed a single female fetus in breech presentation with anterior dorsum, preserved fetal well-being and active fetal movements. The biparietal diameter and amniotic fluid volume were in accordance with gestational age. Three cystic images were observed in the right cerebral hemisphere, the largest measuring 8 x 4 millimeters, deflecting the midline. The largest appeared to extend into the cerebral cortex. The periventricular tissue and cerebral sulci were deformed and displaced by the secondary asymmetric cysts with no evidence of calcifications. No increased echogenicity was observed. The lateral ventricles were normal in size, although deformed, asymmetric, and irregular, with no signs of intraventricular hemorrhage. The third ventricle was normal. Both the corpus callosum and cerebellar

vermis were absent and the septum pellucidum was irregular. The retrocerebellar space had a cystic appearance with dilated cisterna magna. Color Doppler ultrasound showed the presence of only the anterior third of the pericallosal artery (Figure 1). The spine ended normally with no abnormalities. The left eyeball was absent, and the right eyeball measured 10 x 7 millimeters.

In view of the findings, it was decided to perform fetal magnetic resonance imaging, showing a right paramedian cystic image of approximately 9 x 3 millimeters and agenesis of the corpus callosum. Both cerebral hemispheres were asymmetric, being the left one of greater volume, with areas of lesser thickness and blurred border of the gray-white matter in the parieto-occipital lobes (Figure 2). The basal ganglia could not be differentiated from the white matter because of cerebral asymmetry. The asymmetric lateral ventricles had parallel arrangement with cystic images in the choroid plexuses, one on the right of 9 millimeters and two on the left of 4 and 3

FIGURE 1. MORPHOLOGIC ULTRASOUND IMAGES. A) ABSENCE OF CORPUS CALLOSUM, WITH DEFORMED AND IRREGULAR VENTRICLES. B) ASYMMETRIC CYST WITH DEFORMATION AND DISPLACEMENT OF PERIPHERAL TISSUES. C) COLOR DOPPLER IN WHICH ONLY THE PRESENCE OF THE ANTERIOR THIRD OF THE PERICALLOSAL ARTERY IS OBSERVED. D) THE ARROW INDICATES THE ABSENCE OF THE LEFT EYEBALL.





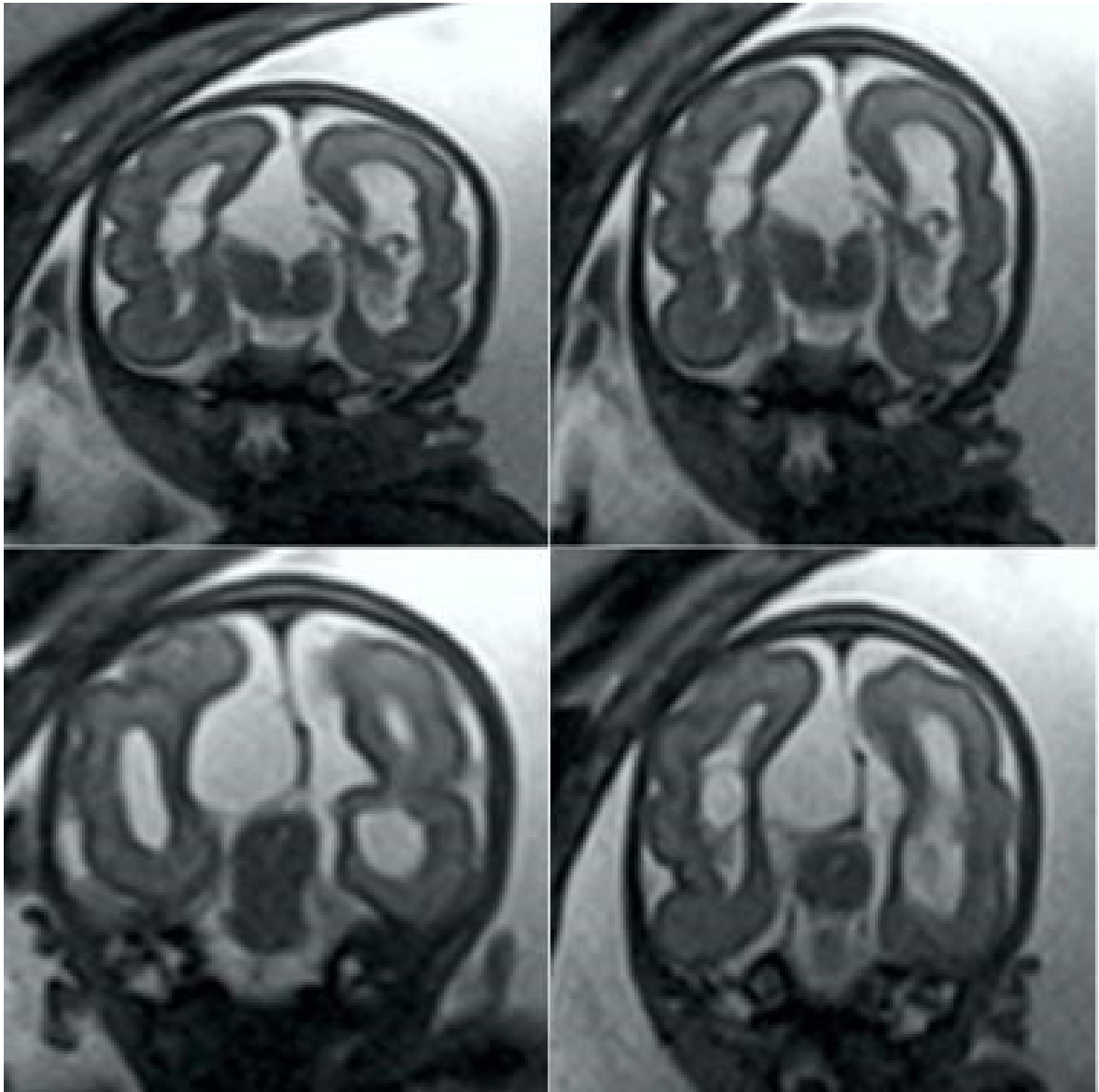
millimeters respectively, with the third ventricle normal. In the posterior fossa, the cerebellum was identified with normal signal and transverse diameter for gestational age, but with a central defect related to the absence of the cerebellar vermis, and a wide cisterna magna with lobulated contours. The brainstem and cerebellum were normal. No intracranial lipomas or cerebral calcifications were observed.

The ocular orbits were of normal size. The left eyeball was noted to be absent, while the right orbit was occupied by a cystic structure whose boundaries were the orbital apex and orbital septum. The fetal profile was normal, although there

was protrusion of the skin tissue on the side of the nose that continued with the right eyelid, along with periocular skin lesions near the outer edge of the right orbit. The subcutaneous cellular tissue was well developed in the cervical region. There was no evidence of cleft lip/palate, defects in the spine, thoracic-abdominal organs and extremities. In view of the neurological, cutaneous and ophthalmological findings, the diagnostic possibility of DOS was considered.

The rest of the pregnancy was uneventful, and it was decided to schedule an elective termination of pregnancy at 38 weeks. A live female newborn was obtained in good general condition, with Ap-

FIGURE 2. FETAL MAGNETIC RESONANCE IMAGING SEQUENCE SHOWING THE ASYMMETRIC CEREBRAL HEMISPHERES AND LATERAL VENTRICLES, TOGETHER WITH THE CYSTIC LESIONS.





gar scores at one minute and 5 minutes of 7 and 9 points, respectively. Initial physical evaluation showed increased volume of the left orbit, without evidence of eyeball, with hypoplastic skin, prominent veins and positive transillumination test, while the left eye was normal. Focal patches of alopecia and dermal hypoplasia of the scalp were also observed, and in the right periocular region there were several mobile cutaneous appendages. Ultrasonography showed fluid-filled cystic areas with no evidence of an eyeball in the right orbit. General examination, including neurological evaluation, showed no abnormalities and the genitalia, hands and feet were normal. The prenatal diagnosis of Dellerman-Oorthuys was confirmed by postnatal MRI. Both echocardiogram and renal ultrasound showed no abnormalities. The newborn was discharged and referred to plastic surgery, ophthalmology and pediatric neurology consultation for treatment and follow-up.

DISCUSSION

DOS, a rare genetic disorder, is characterized by the presence of cutaneous, ophthalmologic and cerebral alterations. Other more severe forms present cleft or cleft palate and hydrocephalus⁽⁴⁾. Unilateral onset of manifestations (usually on the left side) is the most common presentation pattern⁽⁵⁾. In the postnatal period, cutaneous and ocular involvement leads to its identification. Prenatal diagnosis of this condition is usually based on differentiating it from other pathologies⁽³⁾.

The pattern of inheritance is variable, and the specific cause is not known, as most reported cases are sporadic, with no reports of affected siblings⁽⁵⁾. Some investigators have suggested the possibility of somatic mosaicism or sporadic mutations in the fifth or sixth week of fetal development, affecting the development of midline and midbrain structures, when the midbrain-brain boundaries are established⁽⁶⁾. The distribution of the characteristic accessory cutaneous appendages along the fusion line of the facial buds suggests alterations in the closure of the embryonic sulci. Similarly, agenesis of the corpus callosum can be considered as a failure of the commissural fibers^(7,8). Its association to the X chromosome has also been proposed, due to its higher prevalence in males (male:female ratio of 27:7) or because of autosomal dominant inheritance with variable expression⁽⁹⁾.

The clinical manifestations of DOS are usually related to ocular, cerebral and cutaneous alterations. Possible association with cleft palate, underdeveloped orbit, skull defect, cryptorchidism, complex splenic cyst, micrognathia, rib or vertebral malformation and scoliosis has also been reported^(3,10). Brain anomalies include more frequent alterations of the frontal lobe, presence of choroidal cysts and malformations of cortical development. There are also reports of tendon reflex changes and positive Babinski's sign on the side opposite the ocular lesion^(9,11). Neurological abnormalities include seizures, psychomotor developmental disorders (polymicrogyria, colpocephaly, malformations of the ventricular system, hydrocephalus, cystic cavities in the cerebral hemispheres or cerebellum, and agenesis of the corpus callosum). These midline and midbrain malformations are pathognomonic^(9,12).

Associated ocular anomalies include anophthalmia/microphthalmia (unilateral or bilateral) with or without orbital cysts and iris colobomas⁽¹⁾. Orbital cysts have been described as dermoid cysts, orbital encephalocele, cysts with neuroepithelial hamartoma structure, cystic wall surrounded by neuroepithelium and glial tissues or vestigial retinal epithelial tissues^(11,12). Cutaneous alterations include areas of aplasia or focal hypoplasia, alopecia and formation of the characteristic periocular cutaneous appendages. The cutaneous appendages are pink excrescences in some facial areas, most commonly in the periocular area⁽¹²⁾.

Neuroimaging studies are key to the diagnosis of DOS. Other evaluations such as electrocardiogram, echocardiography, abdominopelvic ultrasound and spinal radiography are useful to evaluate associated conditions and to rule out/confirm differential diagnoses. Electroencephalogram is useful in those cases presenting with seizures. Prenatal diagnosis with fetal magnetic resonance imaging is very useful^(1,3). It is not necessary that all features are present to make the diagnosis. Therefore, suggested minimal diagnostic criteria include microphthalmia or orbital cysts, central nervous system cysts or hydrocephalus, and focal skin defects.

The clinical features of DOS may overlap with other established syndromes, which may provide diagnostic dilemmas⁽¹⁾. This syndrome shares features with Goldenhar and Goltz-Gorlin syndromes. The former, also known as oculoauric-



ulovertrebral syndrome, is characterized by the presence of epibulbar dermoid, preauricular cutaneous appendages, vertebral anomalies and absence of cerebral cysts. The second is an X-linked dominant syndrome, which occurs exclusively in females (in males it is lethal), and may present with microphthalmia, coloboma and focal dermal hypoplasia, in addition to polysyndactyly and deficient dentition⁽¹²⁾. Overlap with encephalocraniocutaneous lipomatosis or Haberland syndrome has also been described⁽¹³⁾. In fact, there is some overlap between the two disorders, but this one lacks orbital cysts; and if cutaneous appendages are present, they are not usually located in the periorbital region. In addition, cutaneous hamartomas, epibulbar dermoids and cerebral calcifications are observed. On the other hand, the absence of cerebellar vermis, hypoplastic cerebellar hemispheres and posterior fossa cyst could be confused with Dandy-Walker malformation^(10,12). However, the coexistence of these anomalies with ocular and cutaneous abnormalities may favor the diagnosis of DOS, which is also more devastating and complex. Other differential diagnoses include Aicardi syndrome, microphthalmia syndrome with linear skin defects and focal dermal hypoplasia⁽¹²⁾.

Treatment of DOS is multidisciplinary, symptomatic or supportive. Treatment options include removal of the orbital cyst, removal of cutaneous appendages, repair of palpebral lesions, cleft palate, and insertion of ventriculoperitoneal or cystoperitoneal shunt in cases with hydrocephalus⁽¹⁾. Treatment of the orbital cyst is aspiration, dissection and removal of the cyst and surrounding periocular structures⁽¹⁴⁾. Treatment may involve prolonged anesthesia and extensive dissection, which can be difficult due to brain malformations and associated seizures⁽¹⁵⁾.

The prognosis of patients depends on the severity of brain lesions. There are reports of mental retardation in all affected children older than 16 months⁽¹⁾. In view of this, detailed neurological evaluations are recommended and, if there is any cerebral or cerebellar manifestation, immediate treatment should be initiated to avoid further neurological damage. Long-term follow-up of these patients is also necessary, as seizures and other neurological manifestations may occur with development⁽¹²⁾. Ophthalmologic and pediatric evaluations will also be planned in a coordinated manner, for proper management of affected patients.

In conclusion, DOS is a rare congenital disorder characterized by cutaneous, ophthalmologic, and central nervous system lesions. The disorder is possibly caused by sporadic mutations or somatic mosaicism. Prenatal diagnosis is mainly based on suspicion, as some elements may not be found on routine ultrasound evaluation and some features of the syndrome may be confused with other pathologies with similar characteristics.

REFERENCES

1. Bahmani M, Naseri R, Iraniparast A, Mokhtari R, Jafari SH. Oculocerebrocutaneous Syndrome (Delleman Syndrome): A case with a novel presentation of orbital involvement. *Case Rep Pediatr*. 2021;2021:5524131. doi: 10.1155/2021/5524131
2. Delleman JW, Oorthuys JW. Orbital cyst in addition to congenital cerebral and focal dermal malformations: a new entity? *Clin Genet*. 1981;19(3):191-8. doi: 10.1111/j.1399-0004.1981.tb00695.x
3. Brugger PC, Arzt W, Prayer D. Prenatal diagnosis of Delleman syndrome. *Prenat Diagn*. 2007 Apr;27(4):356-61. doi: 10.1002/pd.1676
4. Moog U, Dobyns WB. An update on oculocerebrocutaneous (Delleman-Oorthuys) syndrome. *Am J Med Genet C Semin Med Genet*. 2018;178(4):414-22. doi: 10.1002/ajmg.c.31667
5. Manudhane A, Arora R, Kapoor S, Rastogi A, Goyal JL. Congenital accessory palpebral aperture--an addition to the spectrum of Delleman syndrome. *Ophthalmic Genet*. 2013;34(1-2):109-11. doi: 10.3109/13816810.2012.729645
6. Boycott KM, Dymont DA, Innes AM. Unsolved recognizable patterns of human malformation: Challenges and opportunities. *Am J Med Genet C Semin Med Genet*. 2018;178(4):382-6. doi: 10.1002/ajmg.c.31665
7. Ugalahi M, Olusanya B, Fasina O, Seidu M, Adekanmi A. Delleman syndrome: A case report from West Africa - features and the challenges of management. *Niger Postgrad Med J*. 2018;25(3):191-4. doi: 10.4103/npmj.npmj_75_18
8. Ortiz-Basso T, Vigo R, Iacouzzi S, Prémoli J. Delleman (oculocerebrocutaneous) syndrome: case report. *Indian J Ophthalmol*. 2014;62(6):741-3. doi: 10.4103/0301-4738.136277
9. Divizia MT, Priolo M, Priolo E, Ottonello G, Baban A, Rossi A, et al. How wide is the ocular spectrum of Delleman syndrome? *Clin Dysmorphol*. 2004;13(1):33-4. doi: 10.1097/00019605-200401000-00009
10. Saldır M, Polat A, Tunc T, Ozge G, Tehli O, Kacar Y, et al. A newborn with oculocerebrocutaneous syndrome (Delleman Oorthuys syndrome). *Genet Couns*. 2015;26(4):457-61.
11. Rizvi SW, Siddiqui MA, Khan AA, Siddiqui Z. Delleman Oorthuys syndrome. *Middle East Afr J Ophthalmol*. 2015;22(1):122-4. doi: 10.4103/0974-9233.148363
12. Chandravanshi SL, Lakhtakia S. Delleman syndrome or Haberland syndrome? *Indian J Dermatol Venereol Leprol*. 2014;80(2):155-6. doi: 10.4103/0378-6323.129400



13. Tian Y, Wang Y, Gao X, Zhang Y, Ju Y. Eye and appearance characteristics of encephalocraniocutaneous lipomatosis. *Eye (Lond)*. 2019;33(2):328-31. doi: 10.1038/s41433-018-0215-z
14. Saatci AO, Arikan G, Saatci P, Saatci Y, Kavukcu S. Oculocerebrocutaneous syndrome. *J Pediatr Ophthalmol Strabismus*. 2008;45(3):181-3. doi: 10.3928/01913913-20080501-19
15. Sadhasivam S, Subramaniam R. Delleman syndrome: anesthetic implications. *Anesth Analg*. 1998;87(3):553-5. doi: 10.1097/00000539-199809000-00009