

## Recurrent acute pancreatitis caused by pancreatic biliary maljunction due to long common channel

Pancreatitis aguda recurrente causada por deficiente unión pancreático-biliar debido a un colédoco largo

Galileu F. A. Farias<sup>1</sup>, Jose P. Otoch<sup>1</sup>, Hugo G. Guedes<sup>1</sup>, Everson L. A. Artifon<sup>1</sup>

<sup>1</sup> Department of Surgery, University of Sao Paulo Medical School. Sao Paulo, Brazil.

Recibido: 22-07-2016

Aprobado: 03-09-2016

### ABSTRACT

The pancreatic biliary maljunction is a rare anomaly that affects mainly females, defined as an anatomical maljunction of the pancreatic duct and the biliary duct confluence, and may be a rare cause of recurrent acute pancreatitis. In order to early diagnosis and prompt treatment, ERCP has an important role in it.

**Keywords:** *Cholangiopancreatography, endoscopic retrograde; Biliary tract diseases; Sphincterotomy, endoscopic (source: MeSH NLM).*

### RESUMEN

La Malformación de la unión biliopancreática es una afección rara y ocurre más en mujeres jóvenes. Es una causa de pancreatitis aguda de causa no conocida. CPRE es una herramienta eficiente para el diagnóstico y también para ser de la terapéutica.

**Palabras clave:** *Pancreatocolangiografía retrógrada endoscópica; Enfermedades de las vías biliares; Esfinterotomía endoscópica (fuente: DeCS BIREME).*

### INTRODUCTION

The biliopancreatic confluence has many types of formats. Because of that the first step during ERCP is a gentle ampulography to make sure that there are no malformation of that area. Also biliopancreatic confluence changes could be a rare cause of recurrent pancreatitis. We present here a case of a female patient with acute pancreatitis and during ERCP it was found an upper insertion of the pancreatic duct laterally to the distal biliary tree.

### CLINICAL CASE

A 25-year-old woman was admitted in a medical emergency for epigastric pain, nausea and vomiting. Laboratory tests revealed high amylase levels, 730 U/ml the diagnosis of acute pancreatitis was performed. The patient reported previous hospitalizations for acute pancreatitis of unknown etiology. No history of other comorbidities and any smoking or alcohol abuse was related.

At the etiological investigation of recurrent pancreatitis, patient underwent an endoscopic ultrasonography which did not show microlithiasis in biliary ducts and an endoscopic retrograde cholangiopancreatography (ERCP) which showed the pancreatic biliary maljunction (PBM) with common channel length about 20 mm and biliopancreatic reflux, without biliary dilatation (Figure 1A). An endoscopic

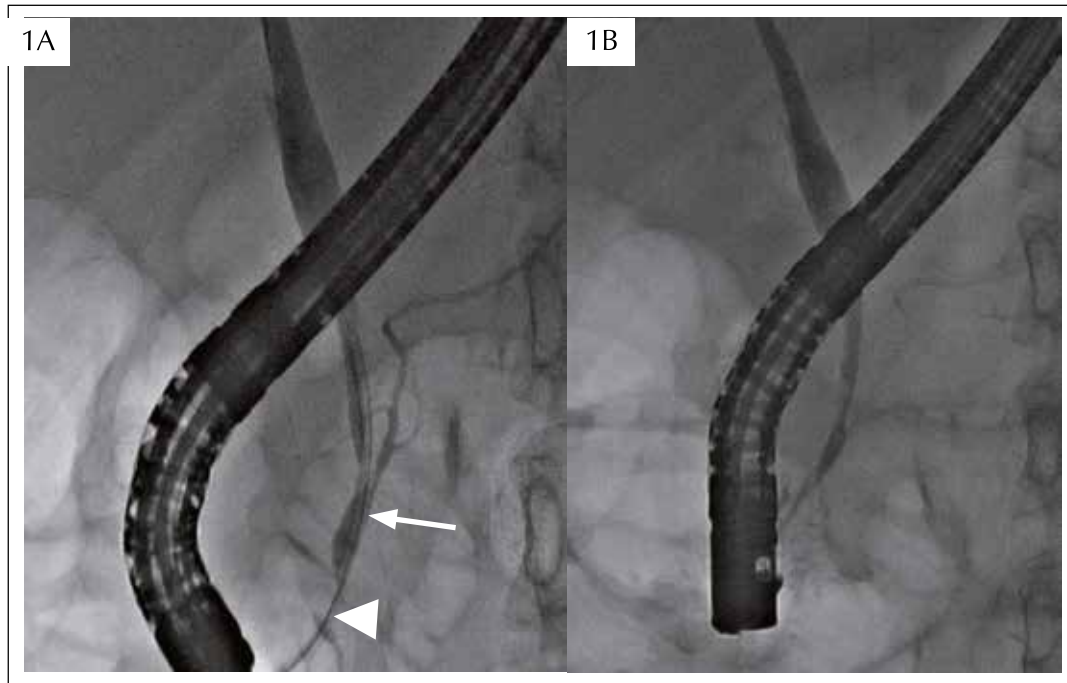
papillotomy was performed for treatment, resulting in a decreased biliopancreatic reflux (Figure 1B).

### DISCUSSION

The pancreatic biliary maljunction is a rare anomaly that affects mainly females, defined as an anatomical maljunction of the pancreatic duct and the biliary duct into of the duodenal wall, forming a common channel<sup>(1)</sup>, whose length typically ranges from 1 mm to 12 mm<sup>(2)</sup>, however may present higher length (>15 mm)<sup>(3)</sup>. It may be associated or no with biliary dilatation.

In PBM, the contraction of the Oddi's sphincter has no function in biliopancreatic junction, and may cause biliopancreatic or pancreatobiliary reflux, which makes PBM an important risk factor for pancreatic and biliary diseases such as acute or chronic pancreatitis, hyperamylasemia, cholangitis and neoplasia. Acute pancreatitis occurs in 13% of patients with a long common channel and is usually relapsing and mild<sup>(4-6)</sup>.

The diagnostic criteria for PBM are the radiological and anatomical detection of the extramural location of the junction of the pancreatic and biliary ducts in the duodenal wall. The ERCP is the most appropriate test for the diagnosis of PBM, being observed union between the ducts despite the contraction of the sphincter of Oddi. The magnetic resonance cholangiopancreatography, 3D-computed tomography,



**Figure 1. A:** ERCP showing the PBM with maljunction with common channel (arrow head) and biliopancreatic reflux (arrow), without biliary dilatation. **B:** ERCP showing the decreased biliopancreatic reflux after endoscopic papillotomy and also a feasible drainage of contrast into the Pancreatic duct.

endoscopic ultrasonography and intraductal ultrasonography can help to make the diagnosis <sup>(7)</sup>.

Treatment of PBM depends on whether it is with or without biliary dilatation. The treatment of PBM with biliary dilatation is prophylactic biliary diversion surgery <sup>(8)</sup>. In PBM without biliary dilatation treatment is controversial in the literature <sup>(9)</sup>. Prophylactic cholecystectomy is performed in many institutions <sup>(10)</sup>.

The ERCP has an important role in order to early diagnosis and prompt treatment by means of sphincterotomy.

**Conflict-of-interest:** The authors declare that they have no competing interests.

**REFERENCES**

1. Kamisawa T, Okamoto A. Biliopancreatic and pancreatobiliary refluxes in cases with and without pancreaticobiliary maljunction: diagnosis and clinical implications. *Digestion*. 2006;73(4):228-36.
2. Dowdy GS Jr, Waldron GW, Brown WG. Surgical anatomy of the pancreatobiliary ductal system. *Observations. Arch Surg*. 1962;84:229-46.
3. Kamisawa T, Egawa N, Nakajima H, Tsuruta K, Okamoto A, Matsukawa M. Origin of the long common channel based on

- pancreatographic findings in pancreaticobiliary maljunction. *Dig Liver Dis*. 2005;37(5):363-7.
4. Kamisawa T, Matsukawa M, Amemiya K, Tu Y, Egawa N, Okamoto A, et al. Pancreatitis associated with pancreaticobiliary maljunction. *Hepatogastroenterology*. 2003;50(53):1665-8.
5. Funabiki T, Matsubara T, Miyakawa S, Ishihara S. Pancreaticobiliary maljunction and carcinogenesis to biliary and pancreatic malignancy. *Langenbecks Arch Surg*. 2009;394(1):159-69.
6. Kamisawa T, Tu Y, Nakajima H, Egawa N, Tsuruta K, Okamoto A, Matsukawa M. Acute pancreatitis and a long common channel. *Abdom Imaging*. 2007;32(3):365-9.
7. Kamisawa T, Takuma K, Itokawa F, Itoi T. Endoscopic diagnosis of pancreaticobiliary maljunction. *World J Gastrointest Endosc*. 2011;3(1):1-5.
8. Matsumoto Y, Fujii H, Itakura M, Matsuda M, Nobukawa B, Suda K. Recent advances in pancreaticobiliary maljunction. *J Hepatobiliary Pancreat Surg*. 2002;9:45-54.
9. Tashiro S, Imaizumi T, Ohkawa H, Okada A, Katoh T, Kawaharada Y, et al. Pancreaticobiliary maljunction: retrospective and nationwide survey in Japan. *J Hepatobiliary Pancreat Surg*. 2003;10(5):345-51.
10. Sugiyama M, Atomi Y. Anomalous pancreaticobiliary junction without congenital choledochal cyst. *Br J Surg*. 1998;85(7):911-6.

**Correspondence:**

Galileu Ferreira Ayala Farias  
 Division of General Surgery, University of Sao Paulo Medical School,  
 E-mail: galileufaf@gmail.com